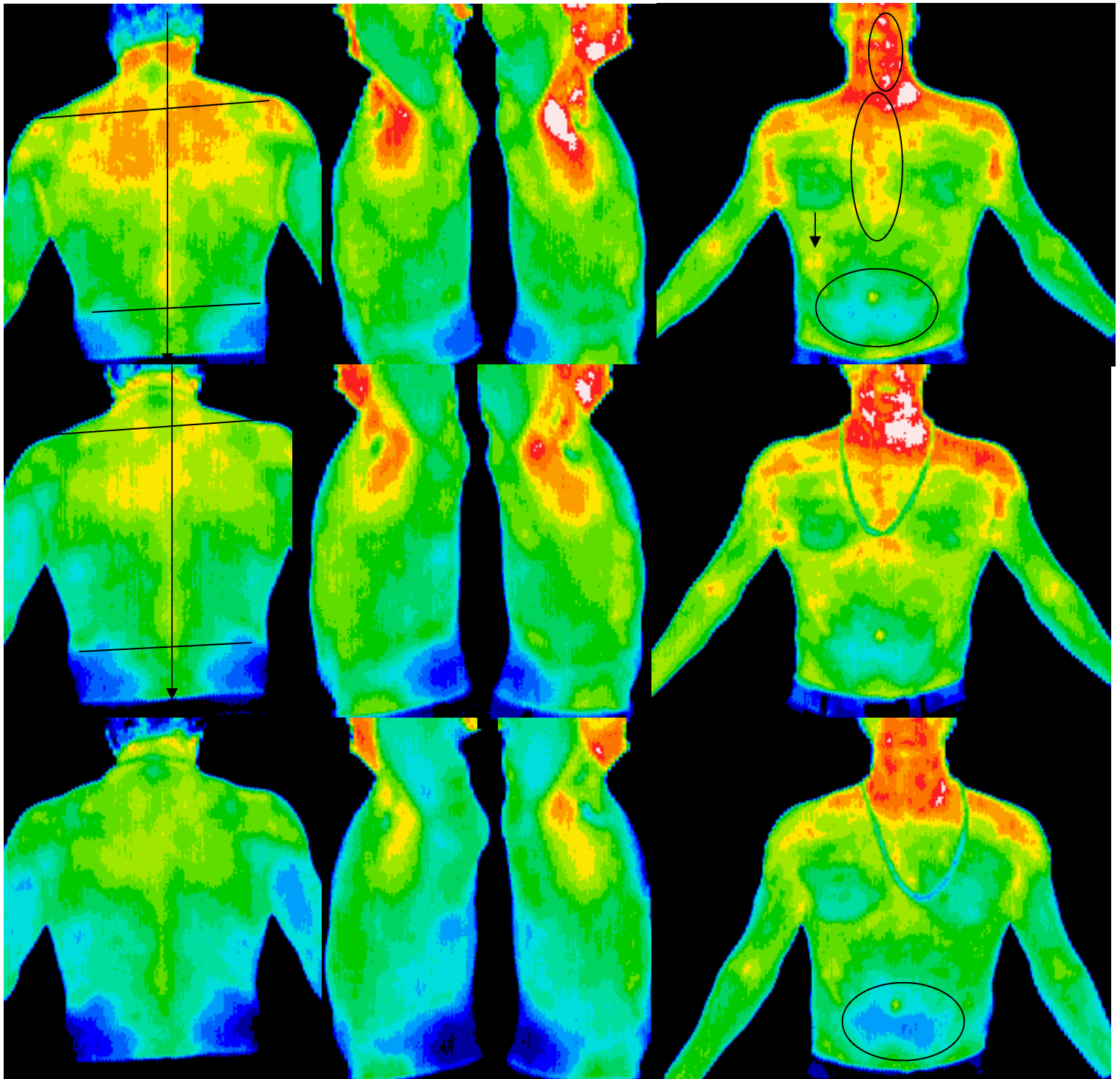


SD Thermal Imaging Report

Thermograms @ 8 degree C color range

8341 La Mesa Blvd., La Mesa Ca. 91941 (619)303-5884
 Name : John Allen Date: 07/09/08 Taken by: Linda Hayes C.T.T. Read by: Greg Melvin ,D.C.,B.C.C.T.



- *Left pelvic drop with left anterior spinal distortion resulting in resulting upper Trapezius myofascial activity.
 - *Right Posterior Deltoid/ left Anterior Deltoid myofascial activity.
 - *Mild right Axillary lymphatic congestion.
 - *Left Periodontal infection with Submandibular Lymphatic involvement.
 - *Stomach/ Pancreas dysfunction with hiatel pressure / esophageal irritation resulting in Ascending Colon inflammation. Central abdominal hypoemissions is associated with Small Intestine dysfunction resulting in digestive disorder.
- *=Findings are consistent with need of clinical correlation

Mild increased in second study noted over the face/ anterior neck region, yet decreases in third study while continuously exposed to cold temperatures.

In this study beads are showing a significant vascular temperature improvement throughout